

Original Research Article

Radiopaque Gelified Ethanol Application in Lumbar Intervertebral Soft Disc Herniations: Croatian Multicentric Study

Karlo Houra, MD, PhD,^{*,†} Darko Perovic, MD, PhD,^{*,‡} Ivan Rados, MD, PhD,^{§,¶} and Drazen Kvesic, MD^{||}

^{*}St. Catherine Hospital, Zabok, Croatia; [†]School of Medicine, University of Rijeka, Rijeka, Croatia; [‡]Clinical Hospital Dubrava, Zagreb, Croatia; [§]Faculty of Medicine Osijek, Josip Juraj Strossmayer University of Osijek, Osijek, Croatia; [¶]Clinical Hospital Center Osijek, Osijek, Croatia; ^{||}Arithera Clinic, Zagreb, Croatia

Correspondence to: Karlo Houra, MD, PhD, St. Catherine Hospital, Bracak 8a, Zabok 49210, Croatia. Tel: 3-854-929-6672; Fax: 3-854-929-6699; E-mail: khoura1912@gmail.com.

Conflicts of interest: The authors report no financial or other conflicts of interest. The authors alone are responsible for the content and writing of the paper.

Abstract

Objective. Minimally invasive percutaneous spinal procedures are popular in trying to reduce spinal pain. The aim of this paper is to evaluate the safety of intervertebral disc chemonucleolysis and to report the effectiveness of a percutaneous, minimally invasive treatment for contained herniated intervertebral discs in the lumbar spine using the recently marketed radiopaque gelified ethanol.

Methods. Pain relief before and after the procedure was self-evaluated by each patient using a verbal numeric scale (VNS) ranging from 0 to 10. Patients were also scored prior to procedure and after chemonucleolysis during several follow-up periods using the Roland-Morris low back pain and disability questionnaire (RMQ). Follow-up periods were defined as 0–6, 6–12, 12–18, 18–24, and 24–30 months. Clinically significant functional improvement (CSFI)

was defined as a decrease of five or more points on the RMQ scale and a decrease of at least 50% of pain intensity using VNS.

Results. Using the RMQ scale, CSFI was achieved in 20/29 patients in the first follow-up period, 20/27 patients in the second follow-up period, 9/12 patients in the third follow-up period, 8/9 patients in the fourth follow-up period, and 4/4 patients in the last follow-up period. Using the VNS rating, CSFI was accomplished in 19/29 patients in the first follow-up period, 19/27 patients in the second follow-up period, 9/12 patients in the third follow-up period, 8/9 patients in the fourth follow-up period, and 4/4 in the last follow-up period.

Conclusions. Intradiscal application of gelified ethanol may be effective in pain reduction using the VNS and Roland-Morris low back pain and disability questionnaire. The treatment is safe and easy to handle.

Key Words. Lumbar Spine; Radicular Pain; Gelified Ethanol

Introduction

Intervertebral disc degeneration with annular tears and subsequent disc herniation is an important cause of radicular pain. However, it is not the only factor causing pain; it is well known that a certain percentage of people with disc degeneration will not experience any kind of pain. When a lumbar degenerated disc protrudes beyond its boundaries and compresses spinal nerve roots, it causes radicular pain in lower extremities, which is responsible for significant functional disability, including impaired ability to work and to engage in social activities. The exact cause of radicular pain is not yet completely understood, but most authors agree that it is due to chemical inflammation around the nerve root and direct or indirect mechanical compression [1]. In the last several decades, a wide range of minimally invasive percutaneous treatments for intervertebral disc herniations

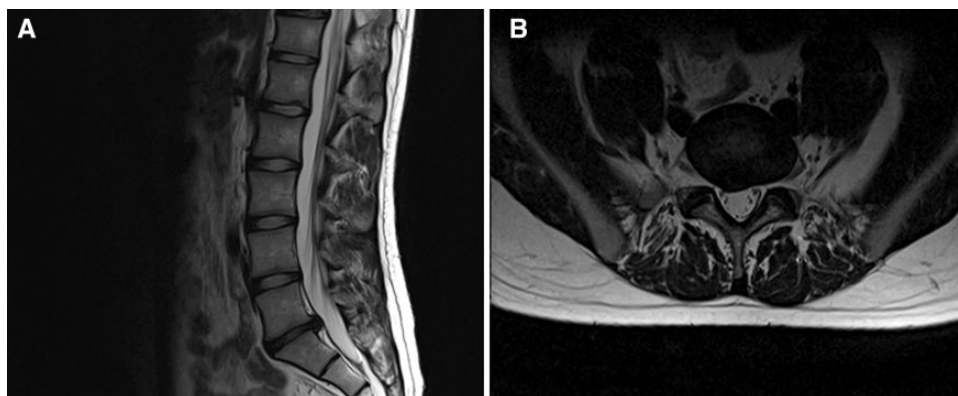


Figure 1 (A) Sagittal T2W magnetic resonance imaging (MRI) of lumbar spine depicting herniation of generatively changed L5-S1 intervertebral disc with the reduction of ventral subarachnoid space. (B) Axial T2W MRI of right-sided dorsolateral soft disc herniation that reduces ventral subarachnoid space.

have been used, starting with chymopapain [2,3] and alcohol chemonucleolysis [4] via percutaneous lumbar discectomy [5], laser disc decompression [6], and intra discal oxygen-ozone therapy [7]. None of these minimally invasive procedures have appeared to be as effective as open surgery [8–14].

Ethanol produces a molecular scission of proteoglycans and glycosaminoglycans of the nucleus pulposus. This leads to a degradation of these components and a loss of their water-retaining capacity, resulting in dehydration and chemical decompression of the disc. Using the properties of alcohol but without its side effects caused by high diffusibility, radiopaque gelified ethanol (DiscoGel) was introduced to the market in past decade [15]. It is made of 96% ethanol, ethylcellulose, which increases the viscosity of the substance, and a third component, tungsten, which is responsible for its radiopaque characteristics. The objective of this study was to evaluate the safety and effectiveness of radiopaque gelified ethanol in patients with radicular pain not responding to conservative medical treatment.

Methods

Patients

From January 2014 to June 2016, 29 consecutive patients who had failed conservative medical therapy for radicular pain were invited to participate in the study, and all agreed to participate. They were examined in three different medical centers by four well-experienced physicians. One physician is a senior anesthesiologist who performs only spine procedures in his everyday pain practice, and other three physicians are surgeons who perform spine interventions but also open spine surgeries on a daily basis. Approval of each hospital ethics committee was obtained, and all patients signed an informed consent prior to enrollment in the study.

Procedure

All patients were evaluated by clinical examination and magnetic resonance imaging (MRI) of the lumbar spine, together with nerve conduction studies. MRI slides of one representative patient with right-sided soft intervertebral disc herniation at the L5-S1 level are shown in Figure 1. Each patient had a duration of symptoms longer than eight weeks and a pain intensity greater than 5/10, as rated by the patient on a verbal numeric scale (VNS). In each patient, radicular pain was predominant compared with low back pain. A second inclusion criterion was failure of conservative treatment, including physical therapy, anti-inflammatory drugs, analgesics, and mild opioids, as well as epidural transforaminal steroid injections. All patients had contained uncalcified disc herniations with disc height greater than 50% of the initial height and Pfirrmann grading of II or III. Exclusion criteria for radiopaque gelified ethanol application were coagulopathy, skin infection, previous spine surgery, calcified disc herniation, disc extrusions with or without free fragment, spinal stenosis, vertebral fractures or systemic infections, and major neurological deficit with impaired sphincter control or motor weakness.

Prior to the procedure, senior experienced nurses not directly involved in the percutaneous procedure evaluated patients for pain intensity using the VNS 0–10, and patients also filled out a standard Roland-Morris low back pain and disability questionnaire [16,17]. At the various follow-up time points, a nurse conducted a telephone interview asking participants to answer questions from the same standard Roland-Morris questionnaire and to rate their pain relief on the VNS.

Technique

All procedures were performed in aseptic conditions in the operating room on an outpatient basis under local anesthesia and intravenous analgesedation. Prophylactic antibiotic (usually 1 g of Cefazolin) was

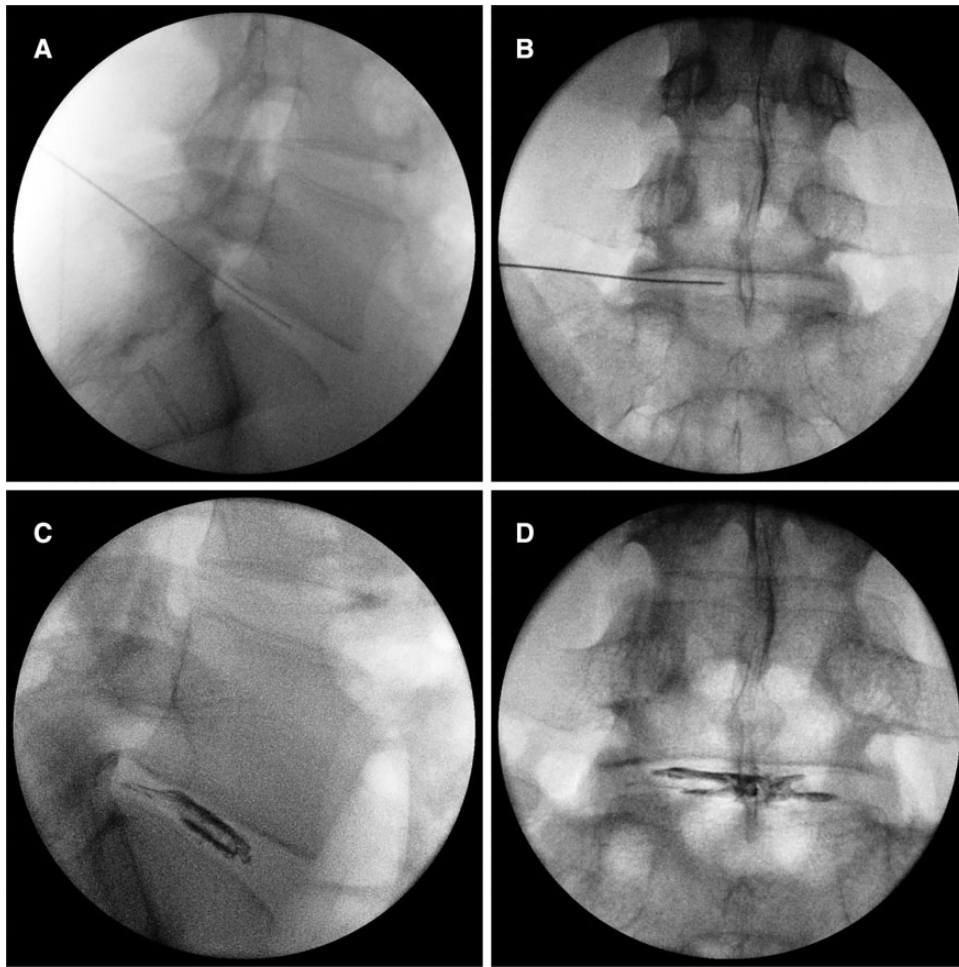


Figure 2 (A) Lateral fluoroscopic image of the lumbar spine depicting needle tip in a center of the L5-S1 disc. (B) Anterior/posterior (AP) fluoroscopic image of the lumbar spine depicting correct needle placement in the center of the disc. (C) Lateral fluoroscopic image after gelified ethanol application. Posterior leakage of gelified ethanol represents annular fissure. (D) AP fluoroscopic image after gelified ethanol application.

administered intravenously 30 minutes before the procedure. Skin was locally anesthetized with 1 to 2 mL of 2% lidocaine chloride. Depending on the BMI and age of each patient, for analgesedation we usually administered up to 1 mg of alfentanil hydrochloride and up to 5 mg of midazolam. Furthermore, all procedures were performed with biplane fluoroscopic guidance utilizing a posterior paravertebral approach with the patient in a prone position.

After squaring the vertebral endplates in anterior/posterior (AP) fluoroscopic view, the targeted intervertebral disc space was identified. The C-arm was then rotated obliquely, until the superior articular process of the inferior vertebra was in the center of the intervertebral disc space. Sometimes, at the L5-S1 level, this could not be achieved due to a pronounced iliac crest, so a less oblique angle was necessary in order to enter the disc. An entry point on the skin was marked using a

blunt Kirchner wire in a manner that its tip projected to the right on the lateral edge of the superior articular process in the middle space of the intervertebral disc. After local anesthesia, a spinal needle of 22 G and 175 mm in length was advanced under tunnel-view fluoroscopic guidance, with the needle tip aiming at the center of the disc, just lateral to the edge of the superior articular process. The depth and the direction of the needle toward the center of the disc were checked with a true lateral and AP views (Figure 2, A and B). We administered from 0.6 to 1.5 mL of radiopaque gelified ethanol with a velocity of 0.1 mL in 30 seconds.

After the procedure, a stilette was induced in the needle, and they both were left inside the disc for at least two minutes before the needle was taken out. This was done to prevent leakage of the gelified ethanol from the puncture site out of the disc. Figure 2, C and D, shows the intervertebral disc after gelified ethanol application.

The procedure usually takes between 30 and 50 minutes to perform for a single level. All patients were observed postprocedure for vital signs, pain, and sensory or motor deficits and were discharged home two hours after the procedure, accompanied by an adult.

Demographic Features

Over a period of 30 months, we treated prospectively 29 patients in three medical centers (17 men, 12 women; age ranged from 20 to 73 years). All patients had predominantly radicular pain. The median duration of symptoms prior to radiopaque gellified ethanol application was nine months (ranging from 2 to 72 months). On MRI scans, isolated disc protrusions were seen on eight patients at level L4-L5, seven at level L5-S1, and two at level L3-L4. In the 12 patients with disc protrusions at two levels, both protrusions were treated. Disc protrusions occurred on the right in 14 patients, on the left in 12 patients, and bilaterally in three patients.

Statistical Analysis

All numeric data were expressed as median and interquartile range (IQR). Clinically significant functional improvement (CSFI) was defined as a decrease of 5 or more points on the Roland-Morris low back pain and disability questionnaire (RMQ) scale [17] and a decrease of at least 50% of pain intensity using VNS. Functional improvement of patients using RMQ scores was calculated according to formula RMQ scores before the procedure – RMQ scored after the procedure at specific follow-up period/RMQ scores before the procedure \times 100 and is expressed as a percentage. The Roland-Morris low back pain and disability questionnaire score and the verbal numeric scale score before and after nucleoplasty were compared with the nonparametric Wilcoxon matched pairs test for dependent samples (P values < 0.01 were considered significant). The statistical program (Statistica for Windows v. 5.0, StatSoft Inc. Tulsa, OK, USA) was used for statistical analysis.

Results

Patient Outcomes

All patients tolerated the procedure well, without serious postprocedural pain or significant discomfort that necessitated significant modification of analgesia. A few felt a transient heat sensation in the injection site that subsided as the injection progressed and disappeared when the needle was withdrawn. In 25% of cases, we observed a transient slight worsening of axial pain over a period of two to three weeks after the procedure. The exact reason for this observation is not known to the authors. Patients who did benefit from the procedure maintained satisfactory symptom relief during a lengthy follow-up. Those who did not benefit from the procedure initially continued to not benefit over time.

Pain intensity using VNS and Roland-Morris low back pain and disability questionnaire scores before and after gellified ethanol application at various follow-up periods for each patient are presented in Tables 1 and 2.

Median pain intensity using VNS prior to radiopaque gellified ethanol application was 7, and in all follow-up periods median pain intensity decreased to 2 (Table 1). A similar trend was observed in RMQ score, which markedly reduced from a median RMQ score of 21 before the procedure to 5 or less at all follow-up periods (Table 2).

Statistical analysis depicts a significant difference in both VNS and RMQ scores ($P < 0.001$) before the procedure against scores in each of the first four follow-up periods. Using the RMQ scale, CSFI was achieved in 20/29 patients in the first follow-up period, 20/27 patients in the second follow-up period, 9/12 patients in the third follow-up period, 8/9 patients in the fourth follow-up period, and 4/4 patients in the last follow-up period. Using the VNS rating, clinically significant pain relief (at least 50%) was accomplished in 19/29 patients in the first follow-up period, 19/27 patients in the second follow-up period, 9/12 patients in the third follow-up period, 8/9 patients in the fourth follow-up period, and 4/4 in the last follow-up period.

Patient Safety

The injection of gellified ethanol was adequately visualized under fluoroscopy and was well distributed in the center of the disc and through the tears into the herniated portion of the disc. In only one patient, who consequently after our radiopaque gellified ethanol application underwent microdiscectomy in other institution, surgeons reported a grayish color in the epidural space. This color can be attributed to tungsten, that is, signaling of gellified ethanol epidural leakage. This leakage, however, did not result in any neurological disturbances, and the patient was pain free after postoperative rehabilitation. Three other patients without epidural leakage underwent operation after gellified ethanol application due to persistent radicular pain. Among these three operated patients, two patients reported poor outcome even after microdiscectomy.

Discussion

To our best knowledge, only 10 papers have been published so far in the medical literature regarding gellified ethanol chemonucleolysis [15,18–26]. Animal studies were not included in these results. Eight of those papers reported use of gellified ethanol in the lumbar spine [15,19,20,22–26], one in the cervical spine [18], and one both in cervical and lumbar disc herniations [21].

The data in Tables 1 and 2 of our study reveal that 27 out of 29 study patients reached six to 12 months of follow-up. The data on our patients shows two relevant features. Every patient who obtained at least 50% relief

Table 1 Verbal numeric scale scores (range = 0–10) of patients before and after radiopaque gelified ethanol application at various times of follow-up

Patient ID	Before treatment	Follow-up, mo				
		0–6	6–12	12–18	18–24	24–30
1	7	2	2	2	2	2
2	7	1	1	1	1	1
3	9	3	3			
4	9	9	9			
5	5	2	2			
6	5	2	2	1	1	
7	5	8	8 (OP)			
8	6	7	7	7		
9	6	1	1	1	1	1
10	8	6	5	6		
11	10	2	2	2	2	2
12	5	4	4	3	3	
13	8	4	2	2	2	
14	7	9 (OP)				
15	9	1	1	1	1	
16	5	2	2	2		
17	7	2	2			
18	8	4	4			
19	7	5	5			
20	6	9 (OP)				
21	5	2	2			
22	8	0	0			
23	5	1	1			
24	8	8	8			
25	8	1	1			
26	9	2	2			
27	7	3	3	3	3	
28	6	2	2			
29	8	5	5 (OP)			
N	29	29	27	12	9	4
Median	7	2	2	2	2	1, 5
IQR	2	3	3	2	1	1
VNS reduced >50%		19/29	19/27	9/12	8/9	4/4
		66%	70%	75%	89%	100%

IQR = interquartile range; OP = patient underwent surgery; VNS = verbal numeric scale.

of pain using the VNS also dramatically improved their Roland Morris low back pain and disability questionnaire score by a magnitude well in excess of the minimal clinically important change for this disability scale.

Only one patient obtained complete relief of pain after gelified ethanol application. Another 18 patients obtained at least 50% relief of pain over the six to 12 months of follow-up. This provides a notional success rate of 19/29 = 66%. When evaluating the success rate of intradiscal gelified ethanol application, the authors would like to emphasize that these results should be viewed in the context that this sample of patients had failed conservative therapy, including a

combination of various analgesics including mild opioids and epidural steroid injections. Further, their MRI scans did not reveal significant disc herniations that would require surgery. As all included patients reported their pain to be a 5 or higher using the VNS and all the abovementioned therapies were ineffective, it is the authors' opinion that a 66% success rate should be considered a significant success.

These results cannot be compared with the results of other authors who presented their work with gelified ethanol application in herniated intervertebral discs for at least two reasons. First, some authors like Papadopoulos [19] and Theron et al. [15] did not use

Table 2 Roland-Morris low back pain and disability questionnaire scores (range = 0–24) of patients before and after radiopaque gelified ethanol application at various times of follow-up

Patient ID	Before treatment	Follow-up, mo				
		0–6m	6–12	12–18	18–24	24–30
1	22	2	2	0	0	0
2	21	4	4	2	2	2
3	24	5	5			
4	24	20	20			
5	15	4	4			
6	18	12	11	8	8	
7	18	20	20 (OP)			
8	21	20	23	22		
9	24	4	4	0	0	0
10	24	20	21	21		
11	23	7	4	4	3	3
12	8	4	4	4	4	
13	21	3	4	3	3	
14	24	24 (OP)				
15	24	2	2	2	2	
16	16	5	4	4		
17	21	5	5			
18	22	8	10			
19	21	18	18			
20	24	24 (OP)				
21	11	1	1			
22	23	5	0			
23	14	1	1			
24	24	24	24			
25	22	5	5			
26	24	6	5			
27	20	10	8	8	8	
28	20	4	4			
29	21	9	9 (OP)			
N	29	29	27	12	9	4
Median	21	5	5	4	3	1
IQR	4	14	7	6	2	2, 5
RMQ > 5		20/29	20/27	9/12	8/9	4/4
FIM median		70%	76%	79%	87%	95%
FIM IQR		63%	43%	38%	32%	11%

FIM = functional improvement; IQR = interquartile range; OP = patient underwent surgery; RNQ = Roland-Morris low back pain and disability questionnaire.

only radiopaque gelified ethanol, but prior to or after it they used other concomitant treatments like radiofrequency, intraarticular steroid injections, and automatized percutaneous discectomy. Second, other authors did not report success rates as at least 50% relief of pain using a VNS score that was corroborated by clinically significant improvement in the Roland Morris disability scale.

Four out of 29 patients (14%) worsened after gelified ethanol application in the six- to 12-month follow-up. Three out of these four patients underwent surgery. It is

the authors' opinion that this pain aggravation is due to the natural course of the disease rather than the negative effect of the intradiscal application of gelified ethanol itself. This thesis is supported by the fact that two out of these three patients were pain free after microsurgery. There was also one other patient who obtained 40% pain relief but consequently still underwent surgery. This patient was unsatisfied with their pain relief even after microsurgery, so we may surmise that the pain generator in this particular patient was located elsewhere and is still unidentified. Four out of 29 patients (14%) obtained some pain relief but have not reached the

threshold of 50% or greater pain relief using VNS. Another two patients (7%) did not have any changes in pain relief using VNS scores. The authors can only speculate about the true reason behind the latter two observations.

Tables 1 and 2 also show that we have followed several (12/29) patients for more than 12 months. The lack of patients in longer follow-up is simply due to the fact that they underwent gelified ethanol application more recently and have not reached longer follow-up yet. The authors deny bias regarding the inclusion of patients in later follow-up as almost all patients (9/12 and 8/9) in longer follow-up appear to be stable and have obtained at least 50% relief of pain. Maintaining positive results in our patients over a longer period after radiopaque gelified ethanol application is in accord with the results of other authors [24,26] whose positive results were unchanged during several months of follow-up. This was also true for our and other studies' patients with negative results from intradiscal gelified ethanol application.

After radiopaque gelified ethanol application, patients reported better reduction of radicular leg pain compared with low back pain. This observation was also true in other published papers and can be attributed to less specificity in the pathophysiology of low back pain as compared with radicular pain [24,26]. Proposed pathophysiological mechanisms for nonspecific low back pain include annulus tears, in-growth of granulation tissue and of nociceptive nerve endings, irritation by chemical materials inside the disc or from the epidural area, and mechanical stimulation associated with lumbar movement on the sinuvertebral nerve ending distributed in the outer third of the annulus and posterior longitudinal ligament [26]. On the other hand, the proposed pathophysiological mechanism of radicular pain is a combination of somatic pain from the outer annulus and posterior longitudinal ligaments and neuropathic radicular pain from nerve root compression together with an inflammatory chemical reaction.

In our study, not all patients underwent MRI follow-up after the gelified ethanol nucleolysis to appreciate the course and progression of disc herniations and to evaluate the possible signal changes of the treated disc and surrounding endplates. In those patients who underwent postprocedural MRI, we observed significant changes in hernia size after more than five months in two cases. It is still unknown why this did not occur in all treated patients even when they obtained pain relief three to 10 weeks after the radiopaque gelified ethanol application. We can only conclude that there is a discrepancy between improvement of clinical symptoms and unchanged findings on MRI scans. Volpentesta et al. [26] and Theron et al. [15] addressed this issue with the presumption that the most important intradiscal therapeutic reaction is not the immediate reduction of the hernia volume but the decrease of the intradiscal pressure, allowing a partial decompressive shift of the

herniated nucleus. de Sèze [24] in his paper proposed that radiopaque gelified ethanol's mechanism of action, in addition to the one mentioned above, may be an ethanol-induced scarring of the annulus fibrosus with consequent reduction of its permeability to the nucleus pulposus, theoretically accomplished by migration of viscous gel toward the herniated breaches. This theory can be questioned as Stagni et al. [23] reported that histopathological analysis of disc specimens 48 hours after the injection disclosed no morphological-structural changes in the nuclear tissue and annulus. Similar findings were presented in a work of Guarnieri et al. [27] while injecting radiopaque gelified ethanol in the intervertebral discs of pigs. They too did not find any morphological-structural changes in nuclear tissue and annulus. It is our opinion that both of these proposed mechanisms of radiopaque gelified ethanol action may be correct, but further molecular research is needed.

During our study, there were no anaphylactic reactions to gelified ethanol and no cases of disc infection despite not using the two-needle technique usually described in other papers [20,24,26]. We followed manufacturer instructions of radiopaque gelified ethanol application using a single spinal needle. In our opinion, if one applies prophylactic antibiotic half an hour before the procedure and carefully avoids touching the tip of the needle during the procedure, there is no need to use larger needles and puncture the skin with an 18-gauge needle.

Our study has several limitations. This prospective, observational, open-label study of a relatively small sample of patients with no control group was unable to evaluate the efficacy of gelified ethanol application. Strengths included full cohort completion of both the the VNS and Roland-Morris low back pain and disability questionnaire, patient recruitment in three centers to reduce selection bias, and conduction of patient interviews by experienced senior nurses not directly involved in the procedure to reduce assessment bias.

Conclusion

Minimally invasive percutaneous chemonucleolysis using radiopaque gelified ethanol in patients with chronic radicular leg pain resistant to conservative treatment did not appear to be more effective than microsurgery, but it reduced pain and disability as measured by the VNS and the Roland-Morris low back pain and disability questionnaire. The treatment was safe and easy to handle, and we did not observe any major complications. The procedure carries fewer complications and risks compared with surgery, and when it fails to help, it does not interfere with subsequent spinal surgery. Our promising results indicate the need for double-blind, randomized controlled studies in larger samples to establish the efficacy of percutaneous radiopaque gelified ethanol as an alternative in the treatment of lumbar disc herniations when conservative treatment has failed.

References

- 1 Kallewaard JW, Terheggen MA, Groen GJ. Discogenic low back pain. *Pain Pract* 2010;10(6):560–79.
- 2 Gogan WJ, Fraser RD. Chymopapain: A 10-year, double-blind study. *Spine (Phila Pa 1976)* 1992;17(4):388–94.
- 3 Fraser RD. Chymopapain for the treatment of intervertebral disc herniation. The final report of a double-blind study. *Spine* 1984;9(8):815–8.
- 4 Riquelme C, Musacchio M, Mont'Alverne F, Tournade A. Chemonucleolysis of lumbar disc herniation with ethanol. *J Neuroradiol* 2001;28(4):219–29.
- 5 Revel M, Payan C, Vallee C, et al. Automated percutaneous lumbar discectomy versus chemonucleolysis in the treatment of sciatica. A randomized multicenter trial. *Spine* 1993;18(1):1–7.
- 6 Grönemeyer DHW, Buschkamp H, Braun M, et al. Image-guided percutaneous laser disk decompression for herniated lumbar disks: A 4-year follow-up in 200 patients. *J Clin Laser Med Surg* 2003;21(3):131–8.
- 7 Gallucci M, Limbucci N, Zugaro L, et al. Sciatica: Treatment with intradiscal and intraforaminal injections of steroid and oxygen-ozone versus steroid only. *Radiology* 2007;242(3):907–13.
- 8 Mariconda M, Galasso O, Secondulfo V. Minimum 25-year outcome and functional assessment of lumbar discectomy. *Spine (Phila Pa 1976)* 2006;31(22):2593–9.
- 9 Moore AJ, Chilton JD, Uttley D. Long-term results of microlumbar discectomy. *Br J Neurosurg* 1994;8(3):319–26.
- 10 Pappas CTE, Harrington T, Sonntag VKH. Outcome analysis in 654 surgically treated lumbar disc herniations. *Neurosurgery* 1992;30(6):862–6.
- 11 Williams RW. Microlumbar discectomy. A conservative surgical approach to the virgin herniated lumbar disc. *Spine (Phila Pa 1976)* 1978;3(2):175–82.
- 12 Kotilainen E, Valtonen S, Carlson CA. Microsurgical treatment of lumbar disc herniation: Follow-up of 237 patients. *Acta Neurochir (Wien)* 1993;120(3–4):143–9.
- 13 Jensdottir M, Gudmundsson K, Hannesson B, et al. 20 years follow-up after the first microsurgical lumbar discectomies in Iceland. *Acta Neurochir (Wien)* 2007;149(1):51–8.
- 14 Davis RA. A long-term outcome analysis of 984 surgically treated herniated lumbar discs. *J Neurosurg* 1994;80(3):415–21.
- 15 Theron J, Guimaraens L, Casasco A, et al. Percutaneous treatment of lumbar intervertebral disk hernias with radiopaque gelified ethanol: A preliminary study. *J Spinal Disord Tech* 2007;20(7):526–32.
- 16 Roland MO, Morris RW. A study of the natural history of back pain. Part 1: Development of a reliable and sensitive measure of disability in low back pain. *Spine (Phila Pa 1976)* 1983;8(2):141–4.
- 17 Stratford PW, Binkley J, Solomon P, et al. Defining the minimum level of detectable change for the Roland-Morris questionnaire. *Phys Ther* 1996;76(4):359–65; discussion 66–8.
- 18 Theron J, Cuellar H, Sola T, et al. Percutaneous treatment of cervical disk hernias using gelified ethanol. *AJNR Am J Neuroradiol* 2010;31(8):1454–6.
- 19 Papadopoulos D, Kostopanagioutou G, Lemonis A, Batistaki C. Intradiscal combination of pulsed radiofrequency and gelified ethanol for the treatment of chronic discogenic low back pain. *Pain Med* 2014;15(5):881–3.
- 20 Touraine S, Damiano J, Tran O, Laredo JD. Cohort study of lumbar percutaneous chemonucleolysis using ethanol gel in sciatica refractory to conservative treatment. *Eur Radiol* 2015;25(11):3390–7.
- 21 Bellini M, Romano DG, Leonini S, et al. Percutaneous injection of radiopaque gelified ethanol for the treatment of lumbar and cervical intervertebral disc herniations: Experience and clinical outcome in 80 patients. *AJNR Am J Neuroradiol* 2015;36(3):600–5.
- 22 Pardatscher K, Volpentesta G, Bombardieri C, Giaquinta A. Percutaneous treatment of lumbar intervertebral disc hernias with discogel. *Neuroradiol J* 2011;24(4):627–35.
- 23 Stagni S, de Santis F, Cirillo L, et al. A minimally invasive treatment for lumbar disc herniations: DiscoGel chemonucleolysis in patients unresponsive to chemonucleolysis with oxygen-ozone. *Interv Neuroradiol* 2012;18(1):97–104.
- 24 de Sèze M, Saliba L, Mazaux J-M. Percutaneous treatment of sciatica caused by a herniated disc: An

Gelified Ethanol Application in Protruded Intervertebral Discs

- exploratory study on the use of gaseous discography and Discogel in 79 patients. *Ann Phys Rehabil Med* 2013;56(2):143–54.
- 25 Leglise A, Lombard J, Moufid A. DiscoGel in patients with discal lumbosciatica. Retrospective results in 25 consecutive patients. *Orthop Traumatol Surg Res* 2015;101(5):623–6.
- 26 Volpentesta G, de Rose M, Bosco D, Stroschio C, Guzzi G, Bombardieri C. Lumbar percutaneous intradiscal injection of radiopaque gelified ethanol (“discogel”) in patients with low back and radicular pain. *J Pain Relief* 2014;3:145.
- 27 Guarnieri G, De Dominicis G, Muto M. Intradiscal and intramuscular injection of discogel—radiopaque gelified ethanol: Pathological evaluation. *Neuroradiol J* 2010;23(2):249–52.