



Intradiscal and Intramuscular Injection of Discogel[®] - Radiopaque Gelified Ethanol: Pathological Evaluation

G. GUARNIERI, G. DE DOMINICIS*, M. MUTO

Neuroradiology Service, The Cardarelli Hospital; Naples, Italy

* Unit of Pathology, The Cardarelli Hospital; Naples, Italy

Key words: Discogel, herniated disc

SUMMARY – *This study assessed the impact and modification of intradiscal, intraforaminal, epidural and intramuscular swine injection of a new material, Discogel[®] - radiopaque gelified ethanol - recently introduced for the mini-invasive treatment of herniated disc. Discogel[®] is a sterile viscous solution containing ethyl alcohol, cellulose derivative product, added to a radio-opaque element, tungsten. The pig was sedated and under fluoroscopy guidance a needle was positioned within disc L1-L2 followed by intradiscal, intraforaminal, epidural and intramuscular injection of 1 ml of Discogel. As disc control level L4-L5 was considered where nothing was injected. The pig was sacrificed 48 h after injection of discogel and the spine from D10 to S1 was removed and fixed in 10% buffered formalin. The anatomical specimens were cut with an electric saw and analyzed by routine technique then stained with formalin. The specimens containing bone material were treated by DEKAL solution. The specimens were stained with hematoxylin-eosin method and then analyzed by histochemical (Masson -Van Gieson PAS and trichromic stains) and immunochemical methods. Morphostructural examination disclosed a granular material coloured black by hematoxylin-eosin method (tungsten) in paravertebral tissue both in the muscular and connective tissue. Some inflammatory elements like lymphomonocyte cells and venous stasis were found. No alteration was found where discogel was injected, and the nucleus pulposus, disc, chondromixoid and root ganglion were normal. After intradiscal, intraforaminal, epidural and intramuscular injection of Discogel[®] no morpho-structural changes in nuclear tissue and annulus were found. Further studies on pigs with immunohistochemical analysis after treatment will confirm the morphological alterations induced by discogel and its action.*

Introduction

Low back pain is one of the commonest spine diseases. The most common cause of low back pain with classical irradiation along the nerve root course is disc protrusion or herniation. In the last twenty years, several minimally invasive percutaneous techniques have been introduced into clinical practice for the treatment of lumbar disc herniations. These include *automated percutaneous lumbar discectomy according to Onik, percutaneous laser disc decompression, intradiscal electrothermal therapy, percutaneous coablation, nucleoplasty, decompressor percutaneous discectomy*, chemodiscolysis with

O₂-O₃ that can represent a safe and alternative therapy option to surgical treatment in selected cases. All of them offer satisfactory clinical outcomes combined with good patient compliance and a low cost. They all require a short hospital stay and can be repeated several times in the same patient.

By different routes, the rationale underlying all minimally invasive percutaneous techniques is to reduce intradiscal pressure and create the space necessary for retropulsion or digestion of the disc with a positive effect on pain¹⁻⁴.

Recently, a preliminary clinical study assessed a new product - gelified ethyl alcohol (Discogel[®]) - for mini-invasive percutaneous

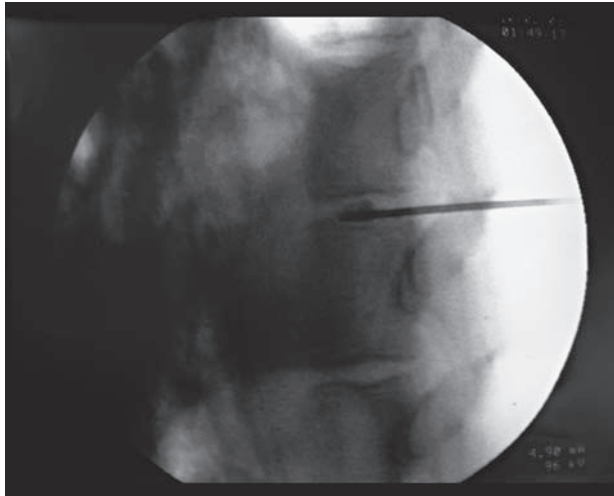


Figure 1 AP view monitoring placement of needle into level L1-L2 with 1ml of Discogel®

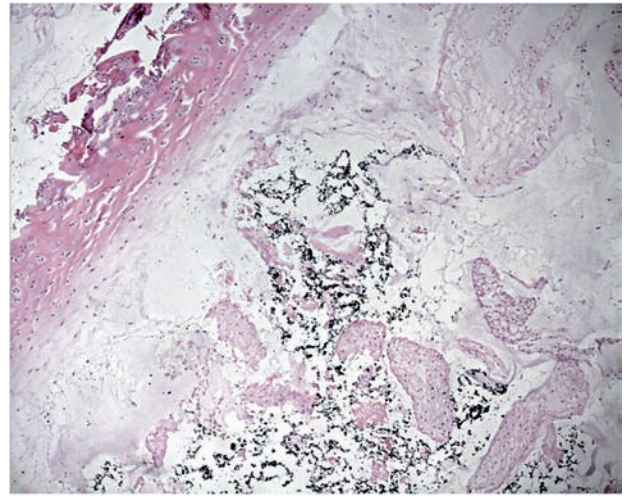


Figure 2 After fixation in hematoxylin-eosin, a normal disc is displayed with regular cellular and extracellular features containing some granular materials colored black by hematoxylin-eosin method corresponding to the tungsten added to the Discogel®.

treatment of herniated disc with a good outcome. It is a sterile viscous solution containing ethyl alcohol, cellulose derivative product, added to a radio-opaque element, *tungsten*, that injected into the vertebral disc, relieves low back, radicular or lumbo-radicular pain⁵.

The aim of our study was to assess the impact and morphostructural modification of swine intradiscal, intraforaminal, epidural and intramuscular injection of this new material.

Material and Methods

At the Biotechnology Research Laboratory of Cardarelli Hospital, a 50 kg pig sedated with pre-anesthesia with Stresnil (15 mg/kg), Ketamin (15 mg/kg) and Atropine (2 mg) then by Propofol (600 mg) and Ketamin (300 mg) was positioned in prone position. Under fluoroscopy guidance, a 20G needle was positioned within disc L1-L2 followed by intradiscal, intraforaminal, epidural and intramuscular injection of 1 ml Discogel (figure 1). As a disc control level L4-L5 was considered where nothing was injected.

The pig was killed 48 h after injection of Discogel and the spine from D10 to S1 was removed and fixed in 10% buffered formalin. The anatomical specimens were cut with an electric saw and analyzed by routine technique then stained with formalin. The specimens were stained with hematoxylin-eosin and then ana-

lyzed by histochemical (Masson -Van Gieson PAS and trichromic stains) and immunochemical methods. The specimens containing bone material were treated with DEKAL solution.

Results

Morphostructural examination disclosed a granular material coloured black by hematoxylin-eosin method (*tungsten*) in paravertebral tissue both in the muscular and connective tissue (figure 2). Some inflammatory elements like lymphomonocyte cells and venous stasis were found (figures 3 and 4). No alteration was found where discogel was injected, and the nucleus pulposus, disc, chondromixoid and root ganglion were normal. After intradiscal, intraforaminal, epidural and intramuscular injection of Discogel® no morpho-structural changes in nuclear tissue and annulus were found (figures 5 and 6).

Discussion

Gelified ethyl alcohol (Discogel®) is a sterile viscous solution containing ethyl alcohol, cellulose derivative product, added to a radio-opaque element, *tungsten*.

According to Theron's preliminary study, 96% pure ethyl alcohol could produce a local necrosis of the *nucleus pulposus* and dehydra-

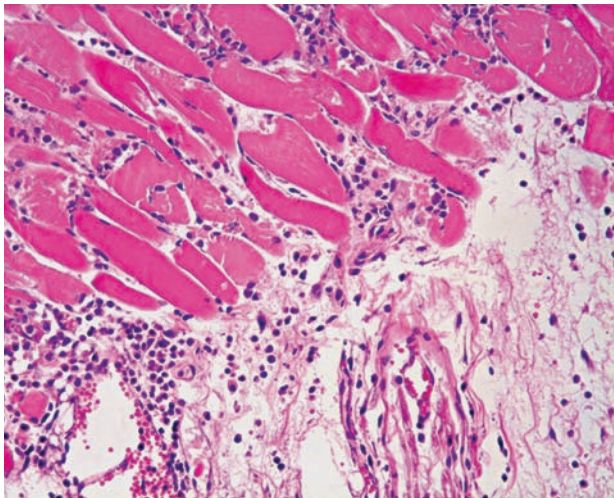


Figure 3

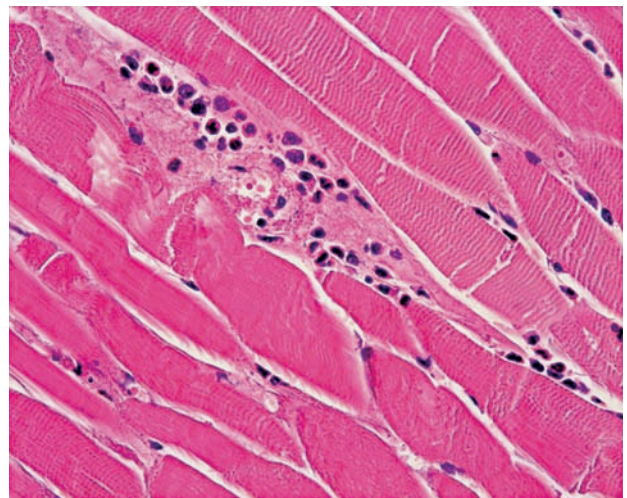


Figure 4

Figures 3 and 4 At the site of paravertebral-intramuscular injection there are some inflammatory elements like lymphomonocyte cells.

tion of the turgescient and protruding disc compressing the peripheral nerves of the spine and causing extreme pain⁵.

The kit contains 2.2 ml of injectable solution with two sterile syringes and two sterile needles to avoid cutaneous contamination. The amount of gel can fill two 1ml syringes.

The indication for Discogel is the treatment of lumbar herniated disc reducing pain syndrome in 91.4% of cases⁵, while it is not indicated for pregnant woman or patients known to be allergic to one of the components, patients in severe depression or for any other condition making the interpretation of pain difficult at radiological control (CT or fluoroscopy guidance).

The injection is performed by post-lateral approach for thoracic or lumbar level and anterolateral approach for the cervical level. Preferably the disc is punctured using a small needle of:

- 20 Gauge for cervical disc (not included in the kit)
- 18 Gauge for thoracic and lumbar discs (included in the kit)

so as to reach the central region of the intraspinal space.

Resuspension of the metallic contrast agent must be homogeneous at the time of its injection. The quantity of gelified ethyl alcohol injected per disc varies between 0.2 and 0.8 mL, according to the dimension of the disc and extent of the hernia. In general, it is recommended to use:

- 0.2 mL of gelified ethyl alcohol for cervical discs
- 0.3-0.5 mL of gelified ethyl alcohol for thoracic discs
- 0.6-0.8 mL of gelified ethyl alcohol for lumbar discs.

At the beginning of the injection the patient may experience a transitional scalding sensation in the region of injection which disappears in the course of injection. To minimize this risk, the product must be injected very slowly. Once the product has been injected, the needle is left in place for two minutes before being withdrawn. The viscosity of gelified ethyl alcohol depends on the temperature. Administration of the product warmed up above room temperature should be avoided because the gel becomes more liquid and is below optimum viscosity. To increase its viscosity gelified ethyl alcohol can be refrigerated just prior to injection¹.

Conclusion

Discogel does not produce any morphostructural changes in contact with nervous structures or muscular tissue. At the moment only a preliminary clinical study on about 276 patients exists. Further studies on pigs with immunohistochemical analysis after treatment will confirm the action of Discogel and the morphological changes induced.

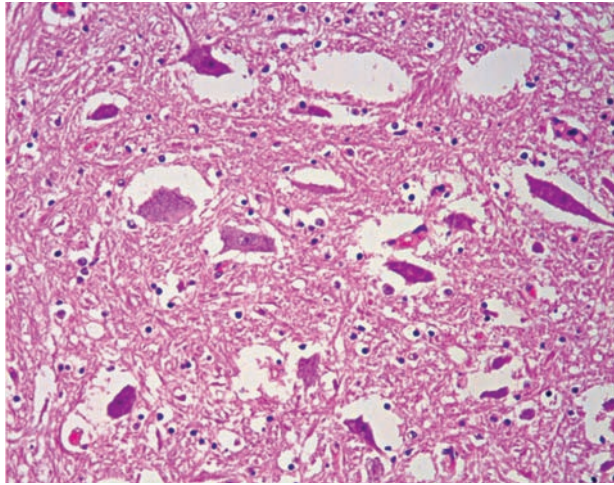


Figure 5

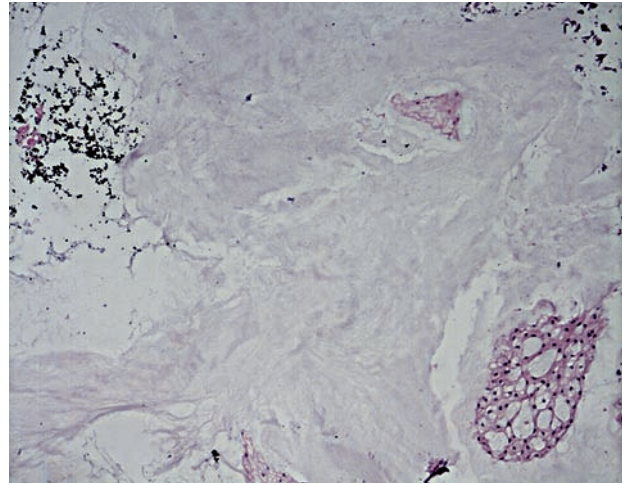


Figure 6

Figures 5 and 6 After fixation in hematoxylin-eosin, a normal aspect of the gangliar tissue and chondromixoid tissue was found.

References

- 1 Guarnieri G, Vassallo, P Muto MG et Al: A comparison of minimally invasive techniques in percutaneous treatment of lumbar herniated discs. A review. *The Neuroradiology Journal* 22: 108-121, 2009.
- 2 Muto M: Alterazioni indotte da infiltrazioni intradiscali e intramuscolari di ossigeno-ozono: studio anatomo-patologico. Risultati preliminari. *Rivista Italiana di Ossigeno-Ozonoterapia* 3: 7-13, 2004.
- 3 Tian JL et Al: Changes of CSF and spinal path-morphology after high concentration ozone injection into the subarachnoid space:an experimental study in pigs. *Am J Neuroradiol* 28: 1051-54, 2007.
- 4 Bonneville JF: Morphological study of the action of chymopapain on the intervetebral disc. A Tournade JP Braun. *Focus on chemionucleolysis*. Ed. Springer-Verlag 1989.
- 5 Theron J, Guimaraens L, Casasco A, Sola T, Cuellar H: Percutaneous treatment of lumbar intervertebral disk hernias with radiopaque gelified ethanol: a preliminary study. *J Spinal Dis Tech* 20 (7): 526-532, 2007.

Dr Gianluigi Guarnieri
Neuroradiology Service
A.O.R.N. A. Cardarelli Hospital
Via Catullo 30
80100 Naples, Italy
Tel.: 00390817473116
Fax: 00390815752281
E-mail: gianluiguarnieri@hotmail.it